



Necrotizing fasciitis: A case report.

Aldo Ronquillo Soxo ¹ *, Aldo Ronquillo Cow ¹ .

1. Outpatient Plastic Surgery Consultation, Complementary Health Network of Guayas, Guayaquil-Ecuador.

Abstract

Introduction: Necrotizing fasciitis (NF) is a rapidly progressive bacterial infection of the skin and soft tissues associated with destruction and necrosis of the fascia. It is usually associated with significant systemic toxicity and affects one per 100,000 inhabitants. Its prognosis depends on early diagnosis and immediate aggressive treatment.

Case report: A 64-year-old man with no pathological history and a two-week history of infection located in the first toe of the right foot with signs of phlogosis, fever, pain, and delirium.

Diagnostic workshop: In the first examination reports, leukocytosis and elevated acute phase reactants were reported without compromising liver or kidney function.

Evolution: With the diagnosis of necrotizing fasciitis, surgery was performed, and the finger was amputated, extending to the dorsal region of the finger. An autograft and multiple healings were needed, and after 120 days of treatment, recovery of the affected tissues was achieved.

Conclusions: FN is a pathology that is increasingly common and is associated with significant morbidity and mortality, given its rapid course and extensive tissue destruction.

Keywords:

Necrotizing fasciitis, Amputation, Case report.

Abbreviations

NF: Necrotizing fasciitis.

Supplementary information

No supplementary materials are declared.

Acknowledgments

Does not apply.

Author contributions

Aldo Renso Ronquillo Soxo: Conceptualization, data curation, funding acquisition, project administration, supervision.

Aldo Ronquillo Vaca: Conceptualization, formal analysis, methodology.

All the authors have read and approved the final version of the manuscript.

Financing

The authors of this article financed the expenses of this research. The costs of studies, antibiotics, and procedures were part of the usual activities of internal medicine services, so they did not constitute additional costs to the patient.

Availability of data and materials

The data sets used and analyzed during the present study are available from the corresponding author upon reasonable request.

Introduction

Necrotizing fasciitis (NF) is a rapidly progressing skin and soft tissue condition associated with the destruction and necrosis of fascia and fat. It is accompanied by systemic toxicity and high mortality [1].

Numerous references to this pathology have existed since ancient times; the first data, from the 5th century, described by Hippocrates, is a fascial necrotizing skin infection. In 1987, a military surgeon, J. Jones, during the American Civil War, reported gangrene, a disease that affected 2,642 soldiers and caused a 50% mortality rate [2].

In 1883, A. Fournier published a detailed description of necrotizing infection of the perineal and genital region [3], currently known as Fournier's gangrene. Meleney established the etiology of hemolytic streptococcus as the cause of FN in 1924 after it was isolated from a sample of 20 patients in Beijing and coined the name acute hemolytic streptococcal gangrene. In 1952, Wilson established the name necrotizing fasciitis [3].

Fascial necrosis is the defining condition of this disease since it is absent in necrotizing cellulitis and myonecrosis.

FN is the most severe form of soft tissue infection, and its prognosis depends on early diagnosis and immediate aggressive treatment. [Table 1](#) presents the classification of necrotizing infections.

Table 1 . Classification of necrotizing infections.

Necrotizing cellulite

Clostridial cellulitis

Clostridial anaerobic cellulitis .

Meleney synergistic gangrene .

Synergistic necrotizing cellulitis .

Necrotizing fasciitis

Type I (polymicrobinan)

Type II (Streptococcal)

Necrotizing myositis/gas gangrene

Pyomyositis

Clinical case

A 64-year-old man with no medical history. After 24 days of bacterial infection, the first toe of the right foot was infected. He was admitted to a public hospital with pain and signs of phlogosis in the right foot that limited motility, radiating to the entire leg, and signs of generalized toxemia. The diagnosis of necrotizing fasciitis was established.

Laboratory tests were performed, and the patient was taken to the operating room, where the first toe of his right foot was amputated, extending it to the dorsal region, and bone resection was performed.

He remained hospitalized for two weeks and received daily treatment. He was re-evaluated for signs of ischemia, so the vascular surgery service recommended amputation of the affected limb up to the supracondylar joint. The patient and family did not accept the treatment and requested discharge and readmission to a private center.

Physical exam

The patient presented with a severe infection of the right foot, with devitalized tissue, signs of phlogosis, and a foul odor ([Figure 1](#)).

Diagnostic workshop

In the first reports of examinations, leukocytosis, and elevated acute phase reactants were reported without compromising liver or kidney function.

Driving

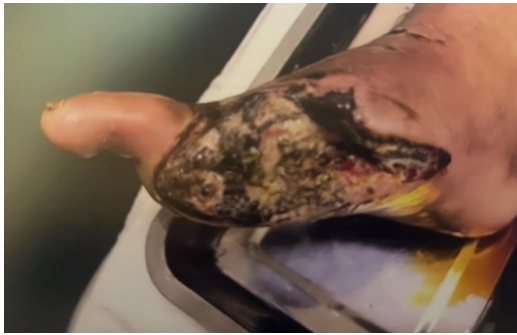The patient had generalized toxemia. He remained hospitalized for 12 days with a treatment plan based on parenteral hydration and antibiotic therapy: third-generation cephalosporin, moxifloxacin, metronidazole, gastric protectors, anti-inflammatory and antiplatelet agents, daily dressings based on iodine solution and collagenase, and dressings every 48 hours with the same treatment protocol. The patient was discharged in stable clinical condition, and his lesion was in the granulation process. The healings were carried out on an outpatient basis and prepared for an autograft in 12 days ([Photo 2-3](#)).

The outpatient controls were cleaned with saline solution and collagenase cream. After 12 days, the patient underwent surgery involving a full-thickness skin autograft obtained from the infraumbilical region. The skin was grafted and fixed with continuous 5-0 nylon stitches, and a Blair-Brown healing process was applied. The area was bandaged with a gauze bandage and a 4 x 3 elastic bandage, and a follow-up appointment was made every eight days ([Photo 4](#)).

Evolution

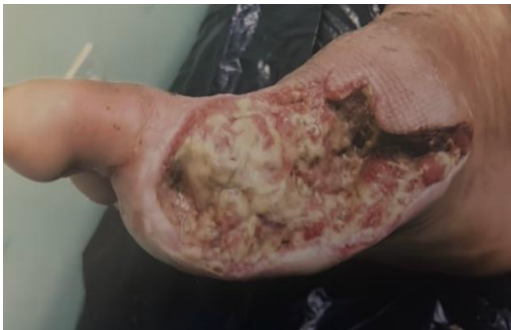After eight days of post-graft control, 85-90% of the grafts survived, and the dressings were supplemented with saline solution, collagenase-neomycin cream, and a Vaseline gauze bandage. A gauze and an elastic bandage covered the affected limb ([Figure 5-6](#)).

Figure 1. Necrotizing fasciitis.



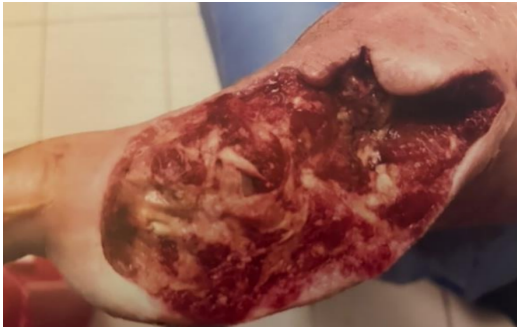Absence of the first toe of the right foot.

Figure 2. Photos of right foot healing.



Day 12.

Figure 3. Evolution photo.



Day 16.

Figure 4. Area of the foot prepared for the graft.

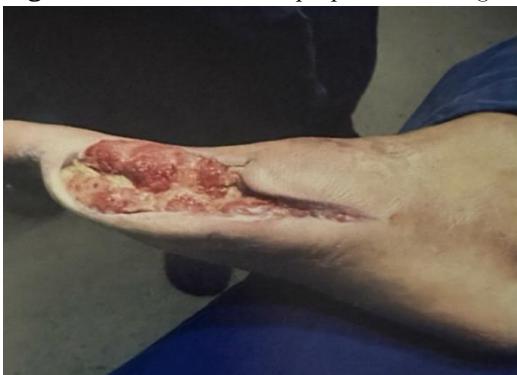
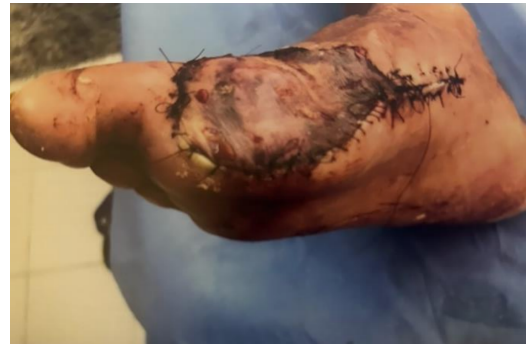
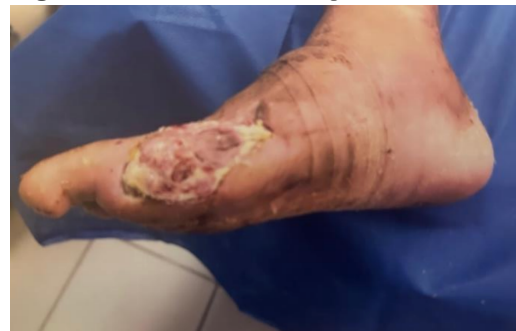Figure 6. Skin autograft.



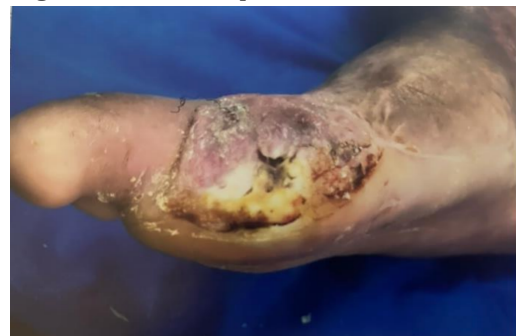Day 30.

Figure 7. Maceration of the graft area.



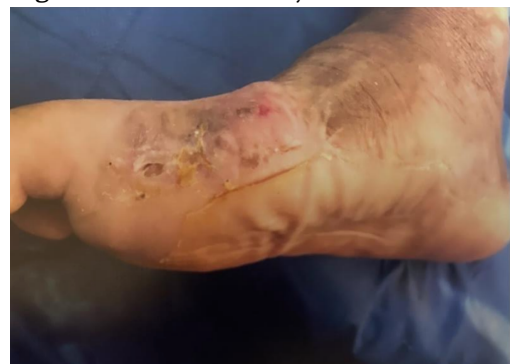Day 42.

Figure 8. Evolution photo.



Day 90.

Figure 9. Final result. Day 120.



The patient underwent maceration in the grafted area, the protocol and dressings with saline solution were followed, and duodenal patches were applied with replacement every four (Figure 7). After three months of total resection of the right second metatarsal of the second toe, we obtained a better response in terms of wound healing, achieving a favorable result (Figure 8 – 9).

Discussion

FN is the most severe form of soft tissue infection that spreads rapidly and can cause death. The onset may be vain as open skin lesions (cuts, scrapes, burns, insect bites, puncture wounds, and surgical wounds) or (for lesions that do not cause skin cuts/contusions or closed trauma) or in patients who have other health problems that weaken the immune system, such as diabetes, kidney disease, cirrhosis or cancer [4].

An incidence of 500-1000 cases per year is estimated in the US, in most countries, and in Western Europe, it has a prevalence of 1 case per 100,000 inhabitants. According to the National Institute of Statistics, in 2009, there were 54 deaths due to FN in Spain, 57.4% of which were men and 43% of which were over 70 years of age.

Depending on the etiological agent, two diagnostic entities can be defined:

FN Type 1 (polymicrobial bacteria, anaerobes, aerobes streptococcus A, and enterobacteria whose synergistic action causes an infection).

Fn type 2 (streptococcal) monomicrobial infection, produced by beta-hemolytic streptococcus of group A, to a lesser extent C and G, most frequently staphylococcus aureus [5].

Fibronectin (FN) must be differentiated from other necrotizing skin conditions, such as necrotizing cellulitis, clostridial cellulitis, clostridial anaerobic cellulitis, clostridial anaerobic cellulitis, synergistic gangrene/meleney, synergistic necrotizing cellulitis, necrotizing myositis/gas gangrene, and pyomyositis, by surgical findings, both histological and microbiologically when clinical suspicion is high; surgical debridement should not be postponed by performing it with an imaging technique whose false negative rate is high; computed tomography (CT) is the imaging study of choice, as it allows for the identification of thickening and edema in the deep fascia and the presence of gas in fascial planes; MRI has a sensitivity of 90-100% and a specificity of 50-80%; and ultrasound and simple radiology are of less utility [6].

Regarding treatment, hemodynamic support measures, extensive early surgical debridement, and antibiotic therapy were used, in addition to measures and general care when necessary. Elevation and immobilization of the affected limb,

sedation, and analgesia with opiates were also used. The severity of the injury requires comprehensive management in an intensive care unit.

Limb amputation is necessary in 20% of patients with FN [7]. Limbs are also amputated in cases of fulminant infection when the infection affects joints or persists after appropriate surgical and antibiotic treatment.

Antibiotic therapy should be administered early and empirically when FN is suspected:

For FN 1, a combination of ampicillin + sulbactam, clindamycin, or metronidazole was used against gram-negative bacteria such as piperacillin or carbapenem.

For FN 2: Penicillin G + clindamycin

Conclusions

FN is a pathological condition that is increasing in incidence and is associated with significant morbidity and mortality, given its rapid course and extensive tissue destruction. FN, in this case, was related to the appearance of septic shock and had a clinical similarity in the initial phases and determining rheumatological pathologies, with a predominance of pain and local inflammatory signs.

Patient perception

The patient stated that he was delighted with the achievement of saving his limb to enjoy a better life and comfort.

References

1. Khamnuan P, Chongruksut W, Jearwattanakanok K, Patumanond J, Tantraworasin A. Necrotizing fasciitis: epidemiology and clinical predictors for amputation. *Int J Gen Med.* 2015 May 14;8:195-202. doi: [10.2147/IJGM.S82999](https://doi.org/10.2147/IJGM.S82999). PMID: 25999758; PMCID: PMC4437611.
2. Singh A, Ahmed K, Aydin A, Khan MS, Dasgupta P. Fournier's gangrene. A clinical review. *Arch Ital Urol Androl.* 2016 Oct 5;88(3):157-164. doi: [10.4081/aiua.2016.3.157](https://doi.org/10.4081/aiua.2016.3.157). PMID: 27711086.
3. Patiño JF, Castro D. Necrotizing lesions of soft tissues: a review. *World J Surg.* 1991 Mar-Apr;15(2):235-9. doi: [10.1007/BF01659058](https://doi.org/10.1007/BF01659058). PMID: 2031360.
4. Sablier F, Slaouti T, Drèze PA, El Fouly PE, Allemeersch D, Van Melderens L, Smeesters PR. Nosocomial transmission of necrotizing fasciitis. *Lancet.* 2010 Mar 20;375(9719):1052. doi: [10.1016/S0140-6736\(10\)60052-9](https://doi.org/10.1016/S0140-6736(10)60052-9). PMID: 20304249.

5. Allaw F, Wehbe S, Kanj SS. Necrotizing fasciitis: an update on epidemiology, diagnostic methods, and treatment. *Curr Opin Infect Dis.* 2024 Apr 1;37(2):105-111. doi: [10.1097/QCO.0000000000000988](https://doi.org/10.1097/QCO.0000000000000988). Epub 2023 Nov 30. PMID: 38037890.
6. Chen LL, Fasolka B, Treacy C. Necrotizing fasciitis: A comprehensive review. *Nursing.* 2020 Sep;50(9):34-40. doi: [10.1097/01.NURSE.0000694752.85118.62](https://doi.org/10.1097/01.NURSE.0000694752.85118.62). PMID: 32826674; PMCID: PMC8828282.
7. Desai V, Vokey S, Vaughan S, Somayaji R. Necrotizing Soft-Tissue Infections: A Case-Based Review. *Adv Skin Wound Care.* 2023 Nov 1;36(11):571-577. doi: [10.1097/ASW.0000000000000060](https://doi.org/10.1097/ASW.0000000000000060). PMID: 37861662.

Statements

Ethics committee approval and consent to participate

Clinical cases are not needed.

Publication consent

The authors have permission for the patient to publish the images and photographs.

Conflicts of interest

The authors declare that there are no conflicts of interest.

Author information

Aldo Renso Ronquillo Soxo, Doctor in Medicine and Surgery from the University of Guayaquil (Ecuador, 2002), a specialist in plastic and reconstructive surgery from the University of Guayaquil (2011), is an attending physician of the plastic surgery service of the Alcívar Hospital.

Email: aldoronquillosoxo@hotmail.es

ORCID <https://orcid.org/0009-0008-2353-0879>

Aldo Ronquillo Vaca, Doctor from the University of Guayaquil (Ecuador, 2024).

ORCID <https://orcid.org/0009-0001-7799-6059>

Editor's Note

The Journal *Actas Médicas* (Ecuador) remains neutral regarding the jurisdictional claims in published maps and institutional affiliations.

Received: March 28, 2024.


Accepted: June 7, 2024.

Published: June 29, 2024.

Editor: Dr. Mayra Ordoñez Martínez.

Cite:

Ronquillo Soxo A, Ronquillo Vaca A. Fasciitis necrotizing: A case report. *Actas Médicas* (Ecuador) 2024;34(1):74-79.

 **Copyright 2024**, Aldo Renso Ronquillo Soxo, Aldo Ronquillo Vaca. This article is distributed under the [Creative Commons CC BY-NC-SA 4.0 Attribution License](https://creativecommons.org/licenses/by-nc-sa/4.0/), which permits noncommercial use and redistribution provided the source and the original author is cited.

Correspondence: * Aldo Renso Ronquillo Soxo. Mail: aldoronquillosoxo@hotmail.es

Address: Av. 8 S-E - Chimborazo 1680-1722, CP 090314, Guayaquil-Ecuador. Phone: (593) 099-712-1777.