



# Efficacy of brachial plexus block in postoperative analgesia in trauma surgeries of the upper limb. A single-center observational study.

Carlos Luis García Santana <sup>1</sup> \*, Carlos Andres Salazar Valarezo <sup>1</sup>

1. Postgraduate in Anesthesia, Faculty of Medical Sciences, University of Guayaquil-Ecuador.

## Abstract

**Introduction:** Brachial plexus block provides multiple advantages in postoperative pain management for surgical procedures in inpatients and outpatients. The study's objective was to determine the effectiveness of brachial plexus block during postoperative pain management in patients undergoing upper limb trauma surgery.

**Methods:** This observational, nonexperimental, descriptive study and qualitative approach was carried out in the Traumatology Service of the Alcívar Clinic of the City of Guayaquil, Ecuador, from January-October 2022, including patients over 18 years of age undergoing trauma surgical procedures with analgesic brachial plexus blocks. Clinical records were applied to obtain variables: age, sex, days of hospitalization, approach, visual analog pain scale, duration of postoperative analgesia, need or not for analgesic rescue, quality of analgesia, and patient satisfaction. The information collected was entered into a Microsoft Excel file and processed with SPSS Statistical Program version 24, according to the proposed objectives.

**Results:** One hundred cases were included. The highest frequency of individuals is male, with an average age of 36. The most commonly used access route was supraclavicular (43.0%). A hospitalization range of 1 to 3 days is described. In addition, a relationship is reported between the most frequent access route and hospital stay ( $X^2: 0.000$ ) and adjuvant treatment ( $X^2: 0.000$ ).

**Conclusions:** Brachial plexus block is suitable as an analgesic method for surgical intervention in upper limb injuries.

### Keywords:

**MeSH:** Analgesia; Pain, Postoperative; Pain Management; Brachial Plexus; Operative Surgical Procedures

### Abbreviations

Not declared.

### Supplementary information

No supplementary materials are declared.

### Acknowledgments

Not declared.

### Author contributions

Carlos Luis García Santana: Conceptualization, data curation, formal analysis, acquisition of funds, research, writing - original draft.

Carlos Andres Salazar Valarezo: Conceptualization, Data curation, Formal analysis, Methodology, Resources, Supervision, Validation, Visualization, Writing - review and editing.

All the authors have read and approved the final version of the manuscript.

### Financing

The authors of this article financed the expenses of this investigation.

### Availability of data and materials

Not declared.

## Introduction

Brachial plexus block is recognized as the most appropriate anesthetic and analgesic technique for upper extremity surgery. Experts consider it the "gold standard" technique, and it reduces the tension, complexity, and complications presented with general anesthesia [1]. The frequency of use is high, between 70% and 97% of the total anesthetic techniques used in upper limb surgeries [2].

Regional upper limb anesthesia can be obtained by using brachial plexus blockade at different stages of its course: trunks, divisions, cords, and terminal branches. The four most used techniques are the interscalene block, the supraclavicular block, the infraclavicular block, and the axillary block. Each technique has its own unique set of advantages and indications for use [3].

The supraclavicular block is most effective for anesthesia of the middle of the humerus and below. Infraclavicular blocks are functional for procedures that require continuous anesthesia. Axillary blocks provide adequate anesthesia distal to the elbow, and interscalene blocks are best suited for the shoulder and proximal upper extremity.

The two most common methods for locating the appropriate nerves for brachial plexus blocks are nerve stimulation and ultrasound guidance. Recent literature on brachial plexus blocks has primarily focused on these two techniques to determine which is more effective. Ultrasound guidance (USG) allows the operator to visualize the position of the needle within the musculature and is especially useful in patients with anatomical variations [1].

In a 2016 cross-sectional observational study [4] conducted in the United Kingdom, with more than 15,000 patients undergoing surgery, 11% reported severe pain, and 37% reported moderate pain in the initial 24 hours. During the 2017-2018 annual report of the Perioperative Quality Improvement Program (PQIP) [4], information was obtained from 79 hospitals across the United Kingdom. It was highlighted that 48% and 19% of patients reported moderate or severe pain in the surgical area on the first postoperative day, respectively, similar to the most recent publication from 2018-2019 [5].

These types of studies are not limited to the United Kingdom. A German prospective cohort investigation [6] of 50,523 patients reported that up to 47.2% of patients experienced severe pain (numerical rating scale score of at least 8) in the first 24 hours after surgery. However, this varied depending on the type of surgery performed. Furthermore, moderate or severe pain extends to the extended postoperative period [7]. These situations occurred despite

pain services that were provided to inpatients, updates, and multidisciplinary postoperative pain management.

The study aimed to determine the effectiveness of brachial plexus block during postoperative pain management of patients undergoing upper limb trauma surgery in a private reference center in Guayaquil, Ecuador.

## Materials and methods

### Study design

The present study is observational and cross-sectional. The source was prospective.

### Scenery

The study was conducted in the Alcívar Hospital Traumatology Service in Guayaquil, Ecuador. The study period was from January 1, 2022, to October 31, 2022.

### Participants

Adult patients over 18 years of age were included, in whom a trauma surgical procedure of the upper extremity was performed and underwent brachial plexus block. Patients with a history of neuropathic pain, osteoarthritis, arthritis, or chronic pain were excluded; patients with more than 10% incomplete medical history and with contraindications for performing locoregional techniques.

### Variables

The variables were age, education, sex, days of hospitalization, brachial plexus block approach, visual analog scale of pain intensity, duration of the analgesic scale, need for adjuvant analgesia, quality of analgesia, and patient satisfaction.

### Data sources/measurements

The source was direct; an electronic form was filled out using data collected from patient surveys. The information was confidential; no personal data were included to identify the study subjects.

### Biases

The leading researcher always maintained the data with a guide and records approved in the research protocol to avoid interviewer, information, and memory biases. Observation and selection bias was avoided by applying participant selection criteria. Two researchers independently analyzed each record in duplicate, and the variables were registered in the database once their agreement was verified.

### Study size

The sample was probabilistic. The annual case list of surgeries in the traumatology and orthopedics service at the Alcivar Hospital in 2022 was taken, corresponding to 12,000. Using the EPI info™ program (Version 7.2.5, CDC, Atlanta, USA, September 2022.) with an expected frequency of 10.3% for upper limb surgeries, a confidence limit of 5%, and a confidence interval of 90%. The sample size was 99 cases.

### Quantitative variables

Descriptive and inferential statistics were used. The results of categorical variables are expressed as frequencies and percentages. Scale variables are defined as the mean and standard deviation.

### Statistical analysis

Noninferential statistics are used for descriptive analysis. In the inferential analysis, a bivariate analysis compares the type of approach versus the hospitalization period and quality of anesthesia. Chi-square tests were used to measure the association. A *P* value less than 0.05 was considered statistically significant.

## Results

### Participants

The study included 100 patients; 20 cases were excluded due to incomplete clinical history.

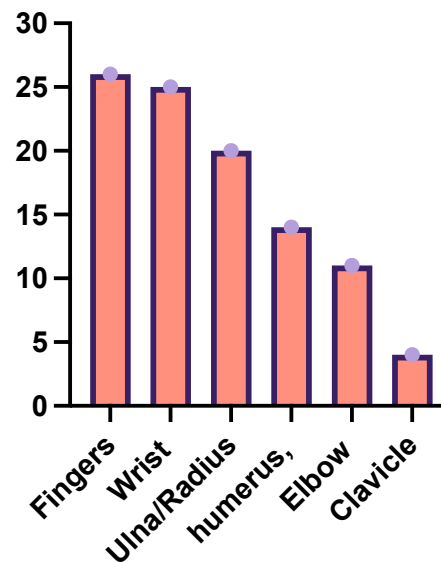
### Description of the study group

There were 100 cases. The sample included 27 women (27.0%) and 73 men (73%). The average age was  $36 \pm 15.2$  years. Education was secondary in 95 cases (95%), and primary and illiteracy were secondary in 5 cases (5%). The type of surgery was osteosynthesis at the level of the upper limb: fingers (26%), wrist (25%), ulna/radius (20%). The details are shown in Figure 1. The hospitalization period in 81 cases (81%) was 1 to 3 days; in 16 cases (16%), 4 to 10 days; and in 3 cases, more than three days.

### Type of brachial plexus block

The majority were of the supraclavicular type; there were no cases of the infraclavicular route ([Table 1](#)).

Figure 1. Type of surgical procedure.



**Table 1** . Approach route for application analgesic for blockage plexus brachial in study participants. \_

Via	N=100
Supraclavicular	44 (44%)
Axillary	38 (38%)
Interscalene	18 (18%)
Infraclavicular	0 (0%)

### Bivariate analysis

The type of approach was associated with a shorter hospitalization time in the case of the supraclavicular and interscalene approaches, in which the association was statistically significant. There was a moderate association between the approach routes and hospitalization time, with a Cramer's V value of 0.245.

According to the quality of analgesia, the three routes were primarily regular, with no significant differences in the association ([Table 2](#)).

**Table 2.** Approach route vs. hospitalization period and quality of analgesia.

Boarding route	Hospitalization Period		x <sup>2</sup>	P value
	1 to 3 days n=82	4 to >10 days n=18		
Supraclavicular	40 (90.9%)	4 (9.1%)	4,222	0.0398
Axillary	31 (81.58%)	7 (18.42%)	0.007	0.9316
Interscalene	11 (61.11%)	7 (38.89%)	6,489	0.0109
Boarding route	Analgesia Quality		x <sup>2</sup>	P value
	Good N=32	Regular n=68		
Supraclavicular	14 (31.82%)	30 (68.18%)	0.001	0.9724
Axillary	14 (36.84%)	24 (63.16%)	0.660	0.4164
Interscalene	4 (22.22%)	14 (77.78%)	0.965	0.3261

### Satisfaction levels

The satisfaction level surveys were as follows:

- 0 not at all satisfied =0.
- 1 little satisfied =0.
- 2 satisfied =0.
- 3 quite satisfied 33 (33%).
- 4 delighted 67 (67%).

### Discussion

In this research, we sought to determine the effectiveness of the brachial plexus block technique during the development of traumatological interventions at the upper limb level. A considerable number of patients were found to undergo this procedure, the predominant male sex, with an average age of 36 years. This similarity was observed in previous studies, which indicate that this technique is applied in young individuals, perhaps because they may be more prone to upper limb injuries due to work and sports activities.

Aksu et al. [8] compared the effects of postoperative analgesia with ultrasound-guided interscalene brachial plexus block and intra-articular bupivacaine in a group of patients undergoing various types of trauma surgeries, with a mean age of 35 years. Likewise, in other investigations focusing on postoperative pain management, the study population obviously corresponded to young adults [9-11].

This research describes the main approaches used for brachial plexus block, with the supraclavicular and axillary being the most frequently used, according to the safety profile reported for them in the literature. Sun et al. [12] established the supraclavicular and axillary routes as a suitable alternative for an analgesic block during upper limb surgeries. Cho et al. [13] described the analgesic and clinical benefits of using the supraclavicular approach in upper limb surgeries, not finding

a significant difference between other routes, thus justifying the investigative development of other interscalene block alternatives.

Ultrasonography in regional anesthesia provides a re-definition for performing some blocks, allowing the application of optional techniques to achieve the same block. For the axillary route, to facilitate the block and reduce the number of needle repositionings during its execution, ultrasound-guided techniques with local anesthetic only around the axillary artery have been described in the literature [14, 15]. These techniques were as effective as the perineural technique, without altering the procedure time, and decreased the incidence of paresthesia during the block [16].

During the postoperative period, 30% to 70% of patients report pain related to the surgical process. To reduce the degree of pain during the postoperative period, techniques such as intra-articular anesthesia, opioids, ketamine, NSAIDs, patient-controlled analgesia (PCA), brachial plexus block, and suprascapular and axillary nerve block are used. Although all of these methods are successful in a certain percentage of cases in managing postoperative pain, the conclusion has yet to be reached as to which is the most effective analgesic technique [17].

The use of brachial plexus block has gained importance recently, with favorable results regarding postoperative analgesia and decreased complications. In this study, a low perception of pain was corroborated, with a minimum hospital stay and requirement for adjuvant therapy in a low number of patients. Based on the information previously presented, it is striking that those individuals who maintained a hospital stay of 24 to 48 hours needed pain management since they manifested a change in the level of sensation from mild to moderate. This need for analgesia can be related to other variables, such as recovery of functionality, the extent of the

initial injury, and the applied surgical technique. However, these variables are not considered for the analysis on this occasion.

It is known that upper limb trauma surgeries are associated with intense postoperative pain [16, 17]. Therefore, a selective block of peripheral nerves provides an alternative analgesia that, affiliated with the preoperative education of the patient, can obtain adequate results. Meng et al. [17] expose the effectiveness of this method in shoulder surgeries by managing continuous infusions, depending on the approach used.

The ultrasound-guided supraclavicular approach to the brachial plexus has a high success rate, including ulnar and musculocutaneous nerve blocks, which may be missed with the interscalene and axillary approaches, respectively [18]. A faster onset time of block is allowed with a reduction in the local anesthetic dose. Among the most studied benefits are the reduction of acute and chronic postoperative pain, postoperative nausea and vomiting, and pulmonary complications [19, 20]. Furthermore, the length of hospital stay is clinically and economically crucial.

This study showed that most participants had a hospital stay of less than three days, with recovery of functionality and adequate pain sensation. The variables mentioned were related, finding a significant statistical relationship between the most frequently used approach routes and the hospital stay. As previously described, in various study cohorts, minor complications are evident depending on the approach used, the most common being supraclavicular and axillary complications, similar to what was reported in this study [14, 16, 21].

The use of adjuvant treatment has been considered a variable to assess the quality of analgesia used in the procedure and pain management after surgery. Although opioids are essential analgesics in relieving perioperative pain, regional anesthesia has improved postoperative pain; opioid consumption and its possible complications have decreased [22-24]. The use of adjuvant pain relief agents and peripheral nerve block (via single injection and continuous infusion) is a widespread practice to reduce opioid dependence during perioperative pain management [25-27]. This study assessed the relationship between the use of adjuvant treatment and the intensity of pain reported by patients. It was found that in those who had short stays (less than 24 hours), only 6% of the participants needed this treatment. A significant association is reported between the access route and the hospitalization period, with a moderate relationship. This association is not the case for the relationship between the quality of adjuvant therapy and the approach, where there is no relationship between these variables.

Finally, the individuals' satisfaction level during their postoperative recovery was assessed based on the sensation of pain perceived, and it was found that a considerable number were satisfied with the results obtained. However, none of the participants reported 100% satisfaction, which has been associated with the recovery course after the surgical intervention. These findings agree with previous reports, in which patients require basic concepts of the technique, especially of its recovery [19]. In another study, the perioperative knowledge of patients was assessed based on the development of informed consent, and poor and deficient knowledge was reported; further studies are needed to obtain solid conclusions regarding the variable in question [28].

## Conclusions

The brachial plexus block is suitable as an analgesic method for surgical intervention in upper limb injuries.

## References

1. Mian A, Chaudhry I, Huang R, Rizk E, Tubbs RS, Loukas M. Brachial plexus anesthesia: A review of the relevant anatomy, complications, and anatomical variations. *Clin Anat*. 2014 Mar;27(2):210-21. doi: [10.1002/ca.22254](https://doi.org/10.1002/ca.22254). Epub 2013 August 20. PMID: 23959836.
2. Venkatraman R, Pushparani A, Karthik K, Nandhini P. Comparison of morphine, dexmedetomidine and dexamethasone as an adjuvant to ropivacaine in ultrasound-guided supraclavicular brachial plexus block for postoperative analgesia-a randomized controlled trial. *J Anesthesiol Clin Pharmacol*. 2021 Jan-Mar;37(1):102-107. doi: [10.4103/joacp.JO-ACP\\_70\\_19](https://doi.org/10.4103/joacp.JO-ACP_70_19). Epub 2021 April 10. PMID: 34103832; PMCID: PMC8174436.
3. Watanabe K, Tokumine J, Lefor AK, Moriyama K, Sakamoto H, Inoue T, Yorozu T. Postoperative analgesia comparing levobupivacaine and ropivacaine for brachial plexus block: A randomized prospective trial. *Medicine (Baltimore)*. 2017 Mar;96(12):e6457. doi: [10.1097/MD.00000000000006457](https://doi.org/10.1097/MD.00000000000006457). PMID: 28328862; PMCID: PMC5371499.
4. Walker EMK, Bell M, Cook TM, Grocott MPW, Moonesinghe SR; Central SNAP-1 Organization; National Study Groups. Patient reported outcome of adult perioperative anesthesia in the United Kingdom: a cross-sectional observational study. *Br J Anaesth*. 2016 June 12;117(6):758-766. doi: [10.1093/bja/aew381](https://doi.org/10.1093/bja/aew381). Erratum in: *Br J Anaesth*. 2017 September 1;119(3):552. PMID: 27956674.
5. Small C, Laycock H. Acute postoperative pain management. *Br J Surg*. 2020 Jan;107(2):e70-e80. doi: [10.1002/bjs.11477](https://doi.org/10.1002/bjs.11477). PMID: 31903595.
6. Gerbershagen HJ, Aduckathil S, van Wijck AJ, Peelen LM, Kalkman CJ, Meissner W. Pain intensity on the first day after surgery: a prospective cohort study comparing 179 surgical procedures. *Anesthesiology*. 2013 Apr;118(4):934-44. doi: [10.1097/ALN.0b013e31828866b3](https://doi.org/10.1097/ALN.0b013e31828866b3). PMID: 23392233.

7. Chapman CR, Donaldson GW, Davis JJ, Bradshaw DH. Improving individual measurement of postoperative pain: the pain trajectory. *J Pain*. 2011 Feb;12(2):257-62. doi: [10.1016/j.jpain.2010.08.005](https://doi.org/10.1016/j.jpain.2010.08.005) . Epub 2011 January 15. PMID: 21237721; PMCID: PMC3052945.
8. Aksu R, Biçer C, Ülgey A, Bayram A, Güneş I, Güney A, Yıldırım MD, Gökahmetoğlu G, Yıldız K. Comparison of interscalene brachial plexus block and intra-articular local anesthetic administration on postoperative pain management in arthroscopic shoulder surgery. *Braz J Anesthesiol*. 2015 May-Jun;65(3):222-9. doi: [10.1016/j.bjane.2014.06.005](https://doi.org/10.1016/j.bjane.2014.06.005) . Epub 2014 October 18. PMID: 25925036.
9. Zeeni C, Abou Daher L, Shebbo FM, Madi N, Sadek N, Baydoun H, et al. Predictors of postoperative pain, opioid consumption, and functionality after arthroscopic shoulder surgery: A prospective observational study. *J Orthop Surg Hong Kong*. 2022;30(1):10225536221094260. <https://doi.org/10.1177/10225536221094260> PMID:3539390832.
10. Reynard F, Vuistiner P, Léger B, Konzelmann M. Immediate and short-term effects of kinesiotaping on muscular activity, mobility, strength and pain after rotator cuff surgery: a crossover clinical trial. *BMC Musculoskelet Disord*. 2018;19(1):305. <https://doi.org/10.1186/s12891-018-2169-5> PMID:30134883 PMCID: PMC6106764
11. Dada O, Gonzalez Zacarias A, Ongaigui C, Echeverria-Villalobos M, Kushelev M, Bergese SD, et al. Does Rebound Pain after Peripheral Nerve Block for Orthopedic Surgery Impact Postoperative Analgesia and Opioid Consumption? A Narrative Review. *Int J Environ Res Public Health*. 2019;16(18):3257. <https://doi.org/10.3390/ijerph16183257> PMID:31491863 PMCID: PMC6765957
12. Sun C, Zhang X, Ji X, Yu P, Cai Medicine (Baltimore). 2021;100(44):e27661. <https://doi.org/10.1097/MD.00000000000027661> PMID:34871240 PMCID: PMC8568401
13. Cho N, Kang RS, McCartney CJL, Pawa A, Costache I, Rose P, et al. Analgesic benefits and clinical role of the posterior suprascapular nerve block in shoulder surgery: a systematic review, meta-analysis and trial sequential analysis. *Anesthesia*. 2020;75(3):386-94. <https://doi.org/10.1111/anae.14858> PMID:31583679
14. Cho S, Kim YJ, Baik HJ, Kim JH, Woo JH. Comparison of ultrasound-guided axillary brachial plexus block techniques: perineural injection versus single or double perivascular infiltration. *Yonsei Med J*. 2015;56(3):838-44. <https://doi.org/10.3349/ymj.2015.56.3.838> PMID:25837194 PMCID: PMC4397458
15. Imasogie N, Ganapathy S, Singh S, Armstrong K, Armstrong P. A prospective, randomized, double-blind comparison of ultrasound-guided axillary brachial plexus blocks using 2 versus 4 injections. *Anesth Analg*. 2010;110(4):1222-6. <https://doi.org/10.1213/ANE.0b013e3181cb6791> PMID:20142336
16. Ferraro LHC, Takeda A, Sousa PCCB de, Mehlmann FMG, Mitsunaga Junior JK, Falcão LF dos R. Randomized prospective study of three different techniques for ultrasound-guided axillary brachial plexus block. *Braz J Anesthesiol*. 2018;68(1):62-8. <https://doi.org/10.1016/j.bjan.2017.04.014> PMID:28651779
17. Meng Y, Wang S, Zhang W, Xie C, Chai X, Shu S, et al. Effects of Different 0.2% Ropivacaine Infusion Regimens for Continuous Interscalene Brachial Plexus Block on Postoperative Analgesia and Respiratory Function After Shoulder Arthroscopic Surgery: A Randomized Clinical Trial. *J Pain Res* 2022;15:1389-99. <https://doi.org/10.2147/JPR.S362360> PMID:35592818 PMCID: PMC9113128
18. Vermeylen K, Engelen S, Sermeus L, Soetens F, Van de Velde M. Supraclavicular brachial plexus blocks: review and current practice. *Acta Anesthesiol Belg*. 2012;63(1):15-21.
19. Cho NR, Cha JH, Park JJ, Kim YH, Ko DS. Reliability and Quality of YouTube Videos on Ultrasound-Guided Brachial Plexus Block: A Programmatic Review. *Healthc Basel Switz*. 2021;9(8):1083. <https://doi.org/10.3390/healthcare9081083> PMID:34442220 PMCID: PMC8394722
20. Smith LM, Cozowicz C, Uda Y, Memtsoudis SG, Barrington MJ. Neuraxial and Combined Neuraxial/General Anesthesia Compared to General Anesthesia for Major Truncal and Lower Limb Surgery: A Systematic Review and Meta-analysis. *Anesth Analg*. 2017;125(6):1931-45. <https://doi.org/10.1213/ANE.0000000000002069> PMID: 28537970
21. Kaye AD, Allampalli V, Fisher P, Kaye AJ, Tran A, Cornett EM, et al. Supraclavicular vs. Infraclavicular Brachial Plexus Nerve Blocks: Clinical, Pharmacological, and Anatomical Considerations. *Anesthesiol Pain Med*. October 2021;11(5):e120658. <https://doi.org/10.5812/aapm.120658>
22. Rupniewska-Ladyko A, Malec-Milewska M. A High Dose of Fentanyl May Accelerate the Onset of Acute Postoperative Pain. *Anesthesiol Pain Med*. 2019;9(5):e94498. <https://doi.org/10.5812/aapm.94498> PMID:31903331 PMCID: PMC6935250
23. Johnson AC, Colakoglu S, Reddy A, Kerwin CM, Flores RA, Iorio ML, et al. Perioperative Blocks for Decreasing Postoperative Narcotics in Breast Reconstruction. *Anesthesiol Pain Med*. 2020;10(5):e105686. <https://doi.org/10.5812/aapm.105686> PMID:34150564 PMCID: PMC8207839
24. Edinoff AN, Fitz-Gerald JS, Holland KAA, Reed JG, Murnane SE, Minter SG, et al. Adjuvant Drugs for Peripheral Nerve Blocks: The Role of NMDA Antagonists, Neostigmine, Epinephrine, and Sodium Bicarbonate. *Anesthesiol Pain Med*. 2021;11(3):e117146. <https://doi.org/10.5812/aapm.117146>
25. Edinoff AN, Houk GM, Patil S, Bangalore Siddaiah H, Kaye AJ, Iyengar PS, et al. Adjuvant Drugs for Peripheral Nerve Blocks: The Role of Alpha-2 Agonists, Dexamethasone, Midazolam, and Nonsteroidal Anti-inflammatory Drugs. *Anesthesiol Pain Med*. 2021;11(3):e117197. <https://doi.org/10.5812/aapm.117197>
26. Suksompong S, von Bormann S, von Bormann B. Regional Catheters for Postoperative Pain Control: Review and Observational Data. *Anesthesiol Pain Med*. 2020;10(1):e99745. <https://doi.org/10.5812/aapm.99745> PMID:32337170 PMCID: PMC7158241
27. Singh N, Gupta S, Kathuria S. Dexmedetomidine vs dexamethasone as an adjuvant to 0.5% ropivacaine in ultrasound-guided supraclavicular brachial plexus block. *J Anesthesiol Clin Pharmacol*. 2020;36(2):238-43. [https://doi.org/10.4103/joacp.JOACP\\_176\\_19](https://doi.org/10.4103/joacp.JOACP_176_19) PMID:33013041 PMCID: PMC7480314
28. Zarnegar R, Brown MRD, Henley M, Tidman V, Pathmanathan A. Patient perceptions and recall of consent for regional anesthesia compared with consent for surgery. *JR Soc Med*. 2015;108(11):451-6. <https://doi.org/10.1177/0141076815604494> PMID:26432814 PMCID: PMC4672254

## Statements

### Ethics committee approval and consent to participate

The ethics committee of the Faculty of Medicine of the University of Guayaquil approved the study.

### Publication consent

Not needed when patient-specific images, X-rays, and studies are not published.

### Conflicts of interest

The authors declare that they have no conflicts of interest.

### Author information

**Carlos Luis García Santana**, Surgeon from the Eloy Alfaro Lay University of Manabí (Ecuador, 2014). Master in Management in Health for him Local development by the Private Technical University of Loja (Ecuador, 2018). Specialist in Anesthesiology from the University of Guayaquil (Ecuador, 2023).

Email: [carlosclgs@hotmail.com](mailto:carlosclgs@hotmail.com)

ORCID <https://orcid.org/0000-0002-8614-4835>

**Carlos Andres Salazar Valarezo**, Doctor from the University of Guayaquil (Ecuador, 2009). Specialist in Anesthesiology and Resuscitation from the Universidad Católica Santiago de Guayaquil (Ecuador, 2015). Postgraduate professor at the University of Guayaquil.

Email: [el\\_caleche@hotmail.com](mailto:el_caleche@hotmail.com)

ORCID <https://orcid.org/0009-0004-9532-1372>

## Editor's Note

Actas Médicas Magazine (Ecuador) remains neutral concerning jurisdictional claims in published maps and institutional affiliations.

Received: July 14, 2023.

Accepted: September 14, 2023.

Published: December 5, 2023.

Editor: Dr. \_ Mayra Ordoñez Martínez.

How to cite this article:

García C, Salazar C. Efficacy of brachial plexus block in postoperative analgesia in trauma surgeries of the upper limb. A single-center observational study. *Medical Records (Ecuador)* 2023;33(2):106-111.



Copyright 2023, Carlos Luis García Santana, Carlos Andres Salazar Valarezo. This article is distributed under the terms of the [Creative Commons CC BY-NC-SA 4.0 Attribution License](https://creativecommons.org/licenses/by/4.0/), which permits noncommercial use and redistribution provided the source and the original author is cited.

Correspondence: Carlos Luis García Santana. Mail: [carlosclgs@hotmail.com](mailto:carlosclgs@hotmail.com)

Address: R492+MJF, Av. Kennedy, Guayaquil 090514. Faculty of Medical Sciences, University of Guayaquil. Telephone (593) (04) 228-1148.