



# Aggressive giant cell tumor bone: case report and review of the literature.

Hugo Ernesto Villarroel Rovere <sup>1</sup> \*, Carlos Alberto Jaramillo Becerra <sup>1</sup> , Gabriel Machado De La Rosa <sup>1</sup> , Manuel Delfilio Encalada Espinoza <sup>1</sup> , Pablo Jiménez Benavides <sup>1</sup> .

1. Orthopedics and Traumatology Service, Alcívar Hospital, Guayaquil, Ecuador.

## Abstract

**Introduction:** Giant cell tumor of bone is a pathology formed by the proliferation of multinucleated giant cells of the osteoclast type mixed with mononuclear cells of benign behavior. It can present locally aggressively and with a tendency to local recurrence. This review aims to describe two surgical clinical cases of giant cell tumors with aggressive behavior and individualized treatment.

**Cases:** We present two cases of highly aggressive giant cell tumors located in the distal radius and proximal tibia, and the results were compared with the literature. The age ranged from 40 to 70 years, and male and female sex was recorded.

**Discussion:** Giant cell tumors are locally aggressive benign neoplasms that can affect the local and surrounding bone structure. The standard treatment is surgery. The therapeutic options will depend on the degree of involvement.

**Conclusion:** GCTs of bone comprise approximately 3% and 5% of primary bone tumors; their behavior is benign but can present locally aggressively. The standard treatment is surgery.

## Keywords:

**MeSH:** Giant Cell Tumors; Giant Cell Tumor of Bone; extremities; Case reports.

## Abbreviations

Not declared.

## Supplementary information

No supplementary materials are declared.

## Acknowledgments

Not declared.

## Author contributions

Hugo Ernesto Villarroel Rovere: Conceptualization, data curation, formal analysis, fundraising, research, writing - original draft.

Carlos Alberto Jaramillo Becerra: Conceptualization, data curation, formal analysis, data analysis, writing - corrections.

Gabriel Machado: Research, Methodology, Software, Writing – original draft.

Manuel Encalada: Research, Methodology, Software, Writing – original draft.

Pablo Jiménez Benavides: Research, Methodology, Software, Writing – original draft, Writing – review and editing.

All the authors have read and approved the final version of the manuscript.

## Financing

The authors of this article financed the costs of this research. The treatment and procedures are a regular part of the pulmonology service, so they did not constitute an additional cost for the patients.

## Availability of data and materials

Not declared.

## Introduction

The giant cell tumor of bone is a low-grade neoplastic pathology formed by the proliferation of osteoclast-type multinucleated giant cells that mix with mononuclear cells; its behavior is benign [1].

It is a neoplasm that affects the epiphysis of long bones (femur, tibia, and radius), represents 3 to 5% of all primary bone tumors, and presents between 20-40 years of age, predominantly female, with a female:male ratio of approximately 1.3:1 [2-5].

The radiological findings present four important parameters: 1) the tumor develops rapidly, 2) the tumor causes lysis of bone tissue at the growth site, 3) the tumor has no osteogenic capacity, and 4) the tumor does not elicit a periosteal reaction [2].

According to the clinical and radiological evaluation, we have the Campanacci classification system: Grade I: intraosseous lesions with well-defined borders and an intact cortex. Grade II: More extensive intraosseous lesions with a thin cortex without loss of cortical continuity. IIA – No pathological fracture. IIB – With pathological fracture. Grade III: Extraosseous lesions that penetrate the cortex and extend into the soft tissues [2-4].

Although a giant cell tumor of bone is a neoplasm that is generally easy to diagnose if complete clinical and radiological information is available, some histological features may make a diagnosis of the lesion complex [1]. A biopsy is needed for the definitive diagnosis. However, biopsy interpretation can be difficult due to the heterogeneity of the tumor. Typical histology shows large multinucleated giant cells interspersed with mononuclear cells that can vary in shape, being round, elongated, spindle-shaped, or polygonal [6].

Surgery is the treatment method of choice for GCTB. Over time, surgical management has improved significantly with advanced imaging to allow for better surgical planning and reconstruction. The use of adjuvant therapies has helped to decrease local recurrence while attempting to maintain high-level limb function [5].

## Clinical cases

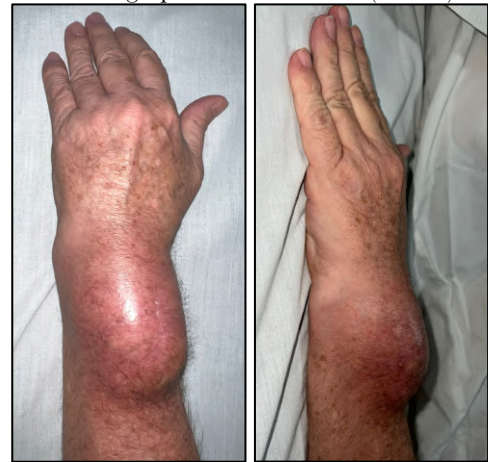### Case 1

A 66-year-old male patient presented with a giant cell tumor in the left distal radius 17 years ago. On that occasion, en bloc resection and placement of the proximal third of the left fibula with plate osteosynthesis was performed, with good evolution and function, until six months ago when it recurred with a fast-growing tumor on the back of the wrist. The physical examination revealed a tumor mass in the left wrist, fixed and painful on palpation, with limited flexion extension (Figure 1). Imaging studies are requested (Figure 2). A biopsy of the left

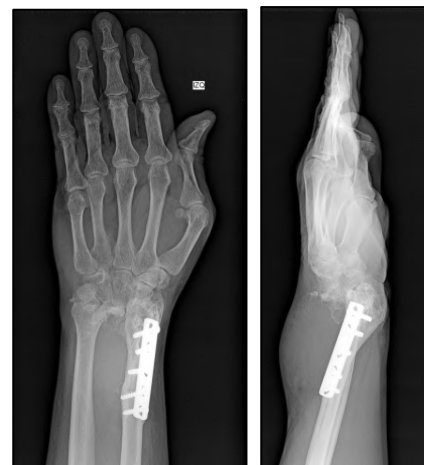wrist lesion was performed with the following results: giant cell bone tumor, recurrent in soft tissues.

In the first stage, the patient is scheduled for the removal of osteosynthesis material from the left distal radius, after which studies pertinent to the case are requested. Magnetic resonance imaging of the left wrist reports a tumor mass that causes bone destruction that extends toward the bones of the first row of the carpus.

**Figure 1.** Photographs of the left wrist (Case 1).



**Figure 2.** Hand and wrist X-ray (Case 1).



X-ray showing osteosynthesis material in the distal radius, absence of lower carpal row in the left wrist.

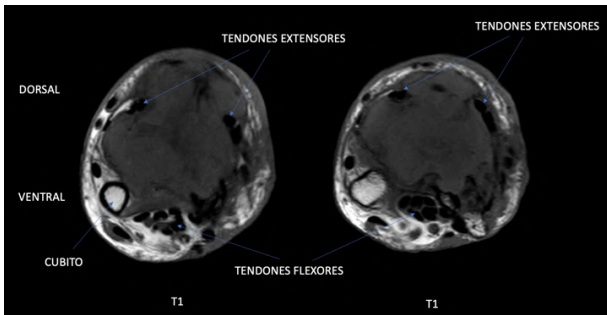
The tumor lesion extends to the musculotendinous soft tissues of the dorsal region, forearm, and wrist. It produces infiltration and surrounds these structures (Figures 3 and 4).

The ultrasound of the left forearm and the median, ulnar and radial nerves explored in all their trajectories did not present alterations. The angiotomography of the upper limbs revealed the radial artery ending in multiple branches for the tumor mass (Figure 5).

With these studies, surgery was scheduled before postoperative evaluation, and resection of the recurrent distal radius tumor and arthrodesis of the left wrist were performed (Figure 6).

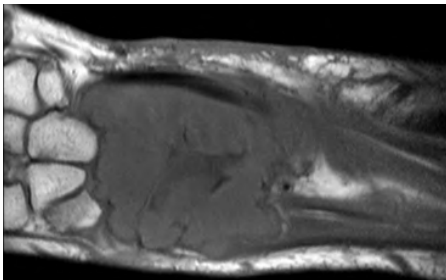
The patient progressed favorably after surgery; after 15 days, the histopathological report was obtained: recurrent giant cell bone tumor in soft tissues, with focal infiltration of the articular cartilage and in contact with the distal surgical edge (Figure 7).

**Figure 3.** Magnetic resonance imaging of the left wrist (case 1)



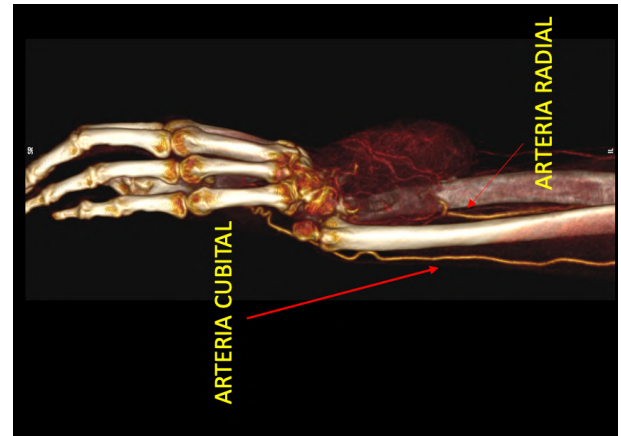
Axial cut in T1 with crushing of the extensor tendons.

**Figure 4.** Magnetic resonance imaging of the left wrist (Case 1).



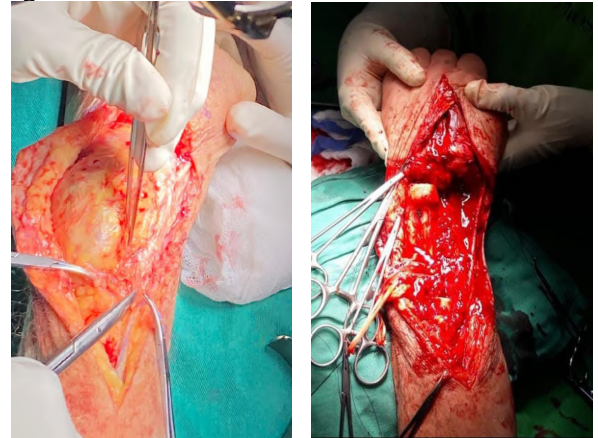
Axial cut in T1 with crushing of the extensor tendons.

**Figure 5.** Angiotomography of the upper limb (Case 1).

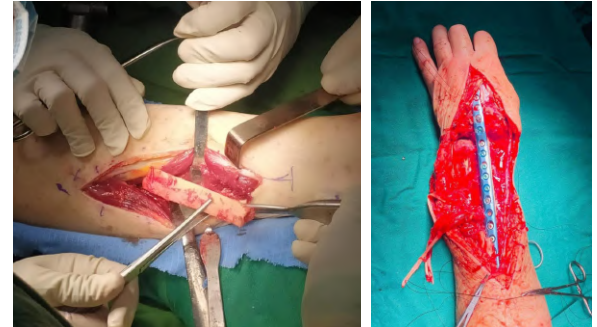


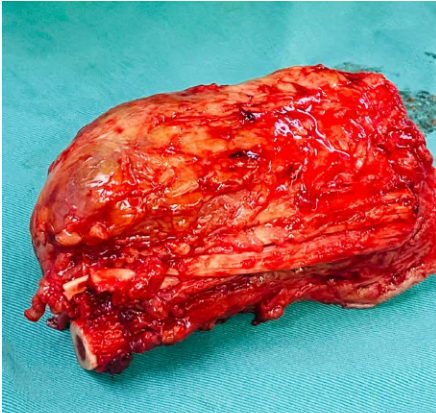
The feeding vessels of the tumor, dependent on the radial artery, are observed.

**Figure 6.** Resection of a recurrent distal radius tumor.

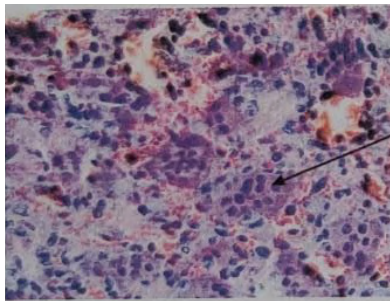


Left wrist arthrodesis



**Figure 7.** Macroscopic histopathological study.

Histological



Recurrent giant cell tumor of bone in soft tissue

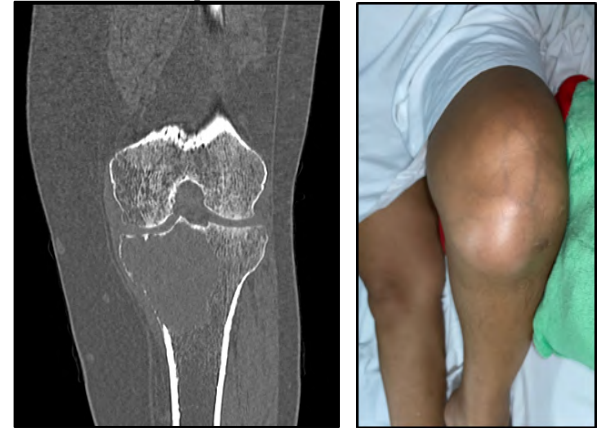## Case 2

A 46-year-old female patient referred to a clinical picture that began in May 2021, characterized by pain in the left knee with no history of trauma. The pain was intensified, with repercussions on the activities of daily living and the impossibility of walking.

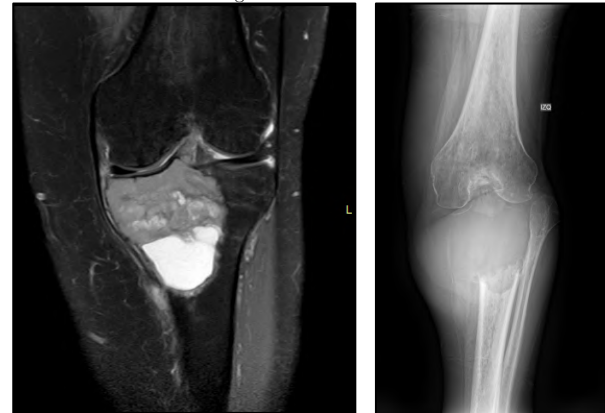The physical examination revealed intense pain in the left knee, decreased range of motion, and quadriceps atrophy. Imaging studies pertinent to the case are requested. X-ray and tomography showed an osteolytic lesion with destruction of the tibial and medial and lateral cortical plates (Figure 8).

With these results, surgery was scheduled before postsurgical evaluation, and transfemoral amputation of the left lower limb was performed (Figure 9).

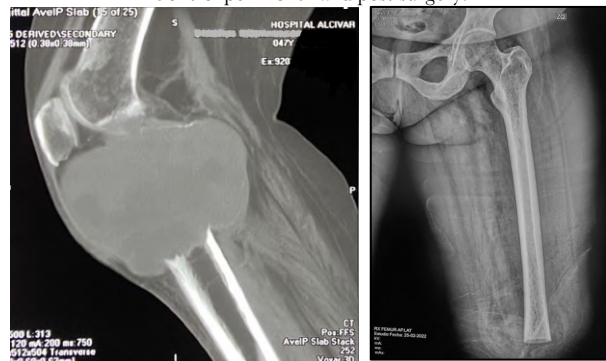
The patient evolved favorably in the postoperative period; after 15 days, the study of the pathology service was reported, finding an aggressive bone giant cell tumor (Campanacci grade 3) with infiltration of surrounding soft tissues and focal extension to the edge of resection; the tibial surgical edge and the distal segment of the femur were free of tumor (Figure 9).

**Figure 8.** Tomographic imaging studies show destruction of the proximal bone cortex of the tibia.

Recurrent giant cell MRI in soft tissues



Control per month and post-surgery.

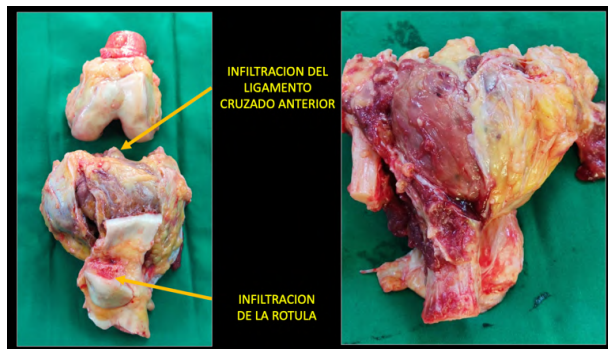


## Discussion

Giant cell tumors of bone comprise approximately 3-5% of primary bone tumors. Its most common location is in the distal femur and proximal tibia (knee), followed by the proximal humerus and distal radius; however, it can be found in the bones of the hands, feet, and the axial skeleton, and it has rarely been described in the craniofacial bones, ribs, and diaphyses of long bones. The average age of presentation is

approximately 30 years, which is unusual in those over 50 years [1-2]. It is a locally aggressive benign neoplasm that can affect the local and surrounding bone structure.

**Figure 9.** Macroscopic study of pathology.



Infiltration of the tumor mass into the anterior cruciate ligament and patella.

We present two cases from our experience of highly aggressive giant cell tumors in different locations and compare the results with the literature. In both cases, the age ranged from 40 to 70 years, male and female sex was recorded, and the limb was affected in the distal radius and proximal tibia. The histological report and clinical behavior were considered to determine the treatment of these patients [3].

Patients with these tumors present with pain, swelling, and an inability to bear weight on the affected limb. In the present cases, the patients showed these characteristic clinical features of the disease [8].

Rigolino et al., in a case report study, found that the patients presented a recurrence of 44% within the first year after surgery. In this work, case 1 showed a recurrence of the lesion 17 years after its initial treatment. Currently, in this case, there is no evidence of local disease six months after its evolution [7].

In its management, it is necessary to be able to rule out distant metastases since this type of tumor is capable of producing pulmonary metastases. Currently, the 2 cases are reported to be clinically stable without metastases [2].

The standard treatment is surgery. The recommended therapeutic options for giant cell tumors of the bone will depend on the degree of involvement: curettage with high-speed drilling and provision of bone graft in Campanacci grades I and II. Grade III tumors, which cannot be treated with the previously mentioned therapeutic option, require en bloc resection and subsequent reconstruction [10].

Amputation has been reserved for cases in which the significant involvement of the soft tissues or the neurovascular bundle prevents oncological resection or seriously compromises the vitality of the limb and would make a comprehensive and ineffective resection, as well as cases in

which the TCG is histologically malignant with extracompartmental extension and a high risk of recurrence [2]. This is how we observed in our case, where after its clinical and imaging evaluation, the amputation of the limb was determined.

New treatments in increasing use can act as adjuvants to the surgical procedure, such as monoclonal antibodies such as denosumab. In 2013, the FDA approved denosumab as a monoclonal antibody that binds to RANKL (receptor activator of nuclear factor ligand). kappa-B) and directly inhibits osteoclastogenesis, producing objective changes in tumors by reducing their stage and improving treatment in cases with recurrence or tumor residue after surgery; however, denosumab does not prevent relapses in patients initially treated with surgery [11].

Regarding the use of salvage radiotherapy after recurrence, it provides a high rate of local control without adding significant morbidity, so it should be indicated as a treatment in cases with resections with limitations in obtaining good safety margins or as palliative treatment.

It is essential to make an early diagnosis and offer better treatment options that can translate into a better quality of life for patients.

## Conclusions

GCTs of bone comprise approximately 3% to 5% of primary bone tumors; their behavior is benign but can present locally aggressively. The standard treatment is surgery. The local aggressiveness of cancer and its ability to produce significant defects and destroy articular surfaces when it affects the limbs sometimes pose real challenges for specialists. Treatment must be individualized for each patient.

## References

1. Echeverri V, Santiago V, Lopez J, Arias L. Giant cell tumor of bone: case series over 64 years in a single center. *Medicine & Laboratory*. 2012;18 (9-10):471-489. URL: [view/308](#)
2. Thomas D, Desai J, Damron T. Giant Cell tumor of bone. UpToDate [Internet]. Uptodate.com. 2022. URL: [Update](#)
3. Bernabé E, Lopez D, Guadalupe O, Enríquez J. Highly aggressive giant cell tumor in the knee. Report of 4 cases. *MEXICAN ORTHOPEDIC ACT*. 2003;13:145-152. URL: [medigraphic/33i](#)
4. Aguilar A, Lopez J. Treatment of giant cell tumors. *Cuban Magazine of Orthopedics and Traumatology*. 2015;29:1-7. *SciELO\_Cuba*: [1116](#)
5. Montgomery C, Couch C, Emory CL, Nicholas R. Giant Cell Tumor of Bone: Review of Current

Literature, Evaluation, and Treatment Options. *J Knee Surg.* 2019 Apr;32(4):331-336. doi: [10.1055/s-0038-1675815](https://doi.org/10.1055/s-0038-1675815). Epub 2018 Nov 16. PMID: 30449024.

6. Basu Mallick A, Chawla SP. Giant Cell Tumor of Bone: An Update. *Curr Oncol Rep.* 2021 Mar 22;23(5):51. doi: [10.1007/s11912-021-01047-5](https://doi.org/10.1007/s11912-021-01047-5). PMID: 33754215.
7. Rigollino AV, Fernando TS, Tanaka MH, Souza MM. Giant cell tumor locally advanced around the knee: treatment and literature review. *Rev Bras Ortop.* 2017 Jun 27;52(4):473-478. doi: [10.1016/j.rboe.2017.06.009](https://doi.org/10.1016/j.rboe.2017.06.009). PMID: 28884107; PMCID: PMC5582821.
8. Montgomery C, Couch C, Emory CL, Nicholas R. Giant Cell Tumor of Bone: Review of Current Literature, Evaluation, and Treatment Options. *J Knee Surg.* 2019 Apr;32(4):331-336. doi: [10.1055/s-0038-1675815](https://doi.org/10.1055/s-0038-1675815). Epub 2018 Nov 16. PMID: 30449024.
9. Wang Y, Shao P, Tian Q, Li H, Li J, Ren P, Lv Z, Lv J, Bai J, Feng Y. 'Triple clear': a systematic and comprehensive surgical process for Campanacci grades II and III giant cell tumors of the bone, with or without pathological fracture and slight joint invasion. *World J Surg Oncol.* 2023 Mar 29;21(1):114. doi: [10.1186/s12957-023-02982-2](https://doi.org/10.1186/s12957-023-02982-2). PMID: 36978172; PMCID: PMC10053671.
10. Abat F, Almenara M, Peiró A, Trullols L, Bagué S, Gràcia I. Giant cell tumor of bone. ninety seven – cases with a mean follow-up of 12 years [Giant cell tumor of bone: a series of 97 cases with a mean follow-up of 12 years]. *Rev Esp Cir Ortop Traumatol.* 2015 Jan-Feb;59(1):59-65. English. doi: [10.1016/j.recot.2014.06.005](https://doi.org/10.1016/j.recot.2014.06.005). Epub 2014 Aug 21. PMID: 25151296.
11. Vagni E., Camacho L, Dell J, Cardenas M, Arango J, Peñaranda J. Giant cell tumor in the distal femur, therapeutic approach. About a case. *Oncological Orthopedics. Scientific Posters.* 2021. [ar/75](https://doi.org/10.1016/j.rboe.2021.06.005).

## Editor's Note

The Revista Actas Médicas (Ecuador) remains neutral regarding jurisdictional claims on published maps and institutional affiliations.

Received: March 11, 2023.

Accepted: May 19, 2023.

Published: June 12, 2023.

Editor: Dr. Mayra Ordóñez Martínez.

## Statements

### Ethics committee approval and consent to participate

Not required for clinical cases.

### Publication Consent

Written permission was obtained from the patient to publish the images.

### Conflicts of interest

The authors declare they have no conflicts of interest.

### Author Information

**Hugo Ernesto Villarreal Rovere**, Specialist in Traumatology and Orthopedics from the University of Guayaquil (Guayaquil, 2004). Doctor of Medicine and Surgery from the University of Guayaquil. Orthopedic-Traumatologist, team member, and director of the postgraduate course in Orthopedics and Traumatology, Hospital Alcívar, Guayaquil, Ecuador.  
Email: villarroelr@hotmail.com

**ORCID** ORCID 0000-0002-0847-0344

**Carlos Alberto Jaramillo Becerra**, Physician from the National University of Loja (Loja, 2002). Specialist in traumatology and orthopedics from the University of Guayaquil (Guayaquil, 2013). High specialty in medicine> Medical and surgical care of spinal conditions by the National Autonomous University of Mexico (Federal District, 2017). Chief, Orthopedics and Traumatology Service, Alcívar Hospital, Guayaquil, Ecuador.  
Email: [dr.jaramilobecerracarlos@gmail.com](mailto:dr.jaramilobecerracarlos@gmail.com)

**ORCID** <https://orcid.org/0009-0002-0680-4547>

**Gabriel Eduardo Machado De La Rosa**, Treating Physician at the Alcívar Hospital Traumatology and Orthopedics Service.  
Email: [gabrielmachado28-10@hotmail.com](mailto:gabrielmachado28-10@hotmail.com)

**ORCID** <https://orcid.org/0009-0007-9306-8141>

**Manuel Delfilio Encalada Espinoza**, Attending Physician at the Hospital Alcívar Traumatology and Orthopedics Service.  
Email: [manuencaespi@gmail.com](mailto:manuencaespi@gmail.com)

**ORCID** <https://orcid.org/0009-0000-0862-318X>

**Pablo Jimenez Benavides**, Resident Physician of Traumatology and Orthopedics Hospital Alcívar.  
Correo: [pabjimenez@hotmail.com](mailto:pabjimenez@hotmail.com)

**ORCID** <https://orcid.org/0009-0007-4813-2247>

Cite:

Villarroel H, Jaramillo C, Machado G, Encalada M, Jimenez P. Aggressive behavior giant cell tumor: case report and review of the literature. Actas Médicas (Ecuador) 2023;33(1):66-72.



Copyright 2023, Hugo Ernesto Villarroel Rovere, Carlos Alberto Jaramillo Becerra, Gabriel Machado, Manuel Encalada, Pablo Jimenez Benavidez. This article is distributed under the terms of the [Creative Commons CC BY-NC-SA 4.0 Attribution License](https://creativecommons.org/licenses/by/4.0/), which permits noncommercial use and redistribution provided the source, and the original author is cited.

Correspondence: Hugo Ernesto Villarroel Rovere

Email: villarroelr@hotmail.com

ORCID: 0000-0002-0847-0344

Address: Colonel 2301 and Azuay. Orthopedics and Traumatology Service, Alcívar Hospital, Guayaquil, Ecuador. Telephone: (5934) 3720100.

---