



Herniated disc resorption without surgical treatment: Case report.

Hugo Ernesto Villarroel Rovere ¹ *, Carlos Alberto Jaramillo Becerra ¹ , Gabriel Machado De La Rosa ¹ , Manuel Delfilio Encalada Espinoza ¹ , Jéssica Tapia Angamarca ¹ .

1. Orthopedics and Traumatology Service, Alcívar Hospital, Guayaquil, Ecuador.

Abstract

Introduction: Lumbar disc herniation is a disease that affects more than 5% of the population; the prevalence of herniated discs is in the range of 1-3% of chronic pain, and only 15% of all cases of LDH have surgical intervention. The main therapeutic plan options include surgical treatment; in some cases, they are maintained with conservative treatment.

Clinical case: A 33-year-old woman with a history of back pain and low back pain for three years; 6 months earlier, after performing a Valsalva maneuver, he presented intense pain 10/10 in the lower back radiating to the inner part of the right thigh and the groin. Difficulty walking and performing daily activities was significant. The pain changed very little with the intake of NSAIDs. On physical examination, the patient had grade 1 obesity and normal blood pressure. There was evidence of a slight decrease in the strength of the right foot during dorsiflexion.

Diagnostic workshop: After imaging studies, a hernia was observed at the L4-L5 level in magnetic resonance imaging of the lumbar spine, located centrally and insinuating toward the body of S1.

Evolution: Bilateral L3-L4, L4-L5, and L5-S1 facet blocks were performed. In subsequent controls, he reported a notable decrease in progressive pain. After three months, he lost weight to a high standard body mass index, and with rehabilitation, he received education in spinal ergonomics in daily activities (spine school). Pain decreased by 90%, referring only to weakness. The disc lesions disappeared between 6 and 12 months in MRI control.

Conclusions: In the present case of a herniated disc, modifiable factors such as obesity and poor ergonomics, once corrected, contributed to the disappearance of spinal lesions and improvement of symptoms.

Keywords:

MeSH: Intervertebral Disc Displacement; Annulus Fibrosus; Intervertebral Disc.

Abbreviations

LDH: herniated disc.
MRI: magnetic resonance imaging.

Supplementary information

No supplementary materials are declared.

Acknowledgments

Not declared.

Author contributions

Hugo Ernesto Villarroel Rovere: Conceptualization, data curation, formal analysis, fundraising, research, writing - original draft.
Carlos Alberto Jaramillo Becerra: Conceptualization, data curation, formal analysis, data analysis, writing - corrections.
Gabriel Machado: Research, Methodology, Software, Writing – original draft.
Manuel Encalada: Research, Methodology, Software, Writing – original draft.
Jéssica Tapia: Research, Methodology, Software, Writing – original draft, Writing – review and editing.
All the authors have read and approved the final version of the manuscript.

Financing

The authors of this article financed the costs of this research. The treatment and procedures are a regular part of the pulmonology service, so they did not constitute an additional cost for the patients.

Availability of data and materials

Not declared.

Surgery

Introduction

Lumbar disc herniation is a common disease that affects approximately more than 5% of the population; the prevalence of herniated discs is in the range of 1-3% of chronic pain, which accounts for only 15% of all cases of LDH had surgical intervention [1-4]. The typical location is L5-S1, followed by L4-L5 and L3-L4. The most frequent herniated discs are posterolateral discs, which compress the root as it exits the spinal cord. In this way, the posterolateral herniation of the disc located between L4 and L5 will compress the L5 root [5]. Among the main therapeutic options, they include surgical treatment, and in some cases, they are maintained with conservative treatment [2, 6].

The study conducted by Ming Zhong et al. showed in their meta-analysis that the overall incidence of spontaneous resorption after LDH was 66.66%. In all, 11 articles came from the UK, Japan, France, Korea, and Italy, although most were from the UK and Japan. The incidence of spontaneous resorption in the UK was 82.94%, while the incidence in Japan was 62.58% [7].

The protrusion of the nucleus pulposus from the disc that contains it causes signs and symptoms depending on the segment of the affected spine [4]. It should be emphasized that not all herniated discs are necessarily symptomatic; the presence or absence of symptoms depends on the size, location, and extent of the herniated disc material concerning the spinal canal and whether the nerve roots are compromised [8].

Therefore, the symptoms are not necessarily related to the imaging results; in studies carried out as a diagnostic complement, morphological alterations of the spine and intervertebral discs can be observed [5]. Symptoms of a herniated lumbar disc include pain that spreads to the buttocks, legs, and feet (sciatica), accompanied by tingling or numbness in the legs or feet and muscle weakness.

We will describe the case of herniated disc reabsorption without surgical treatment, in which the patient received conservative treatment based on physical therapy, analgesics, and spine school for six months with control periods.

This study presents a case in which the resorption of a lumbar hernia is evidenced, treated conservatively, and with beneficial results in terms of symptoms.

Clinical case

Clinical history

A 33-year-old female patient with a personal pathological history of back pain and low back pain for the past three years; 6 months earlier, after performing a Valsalva maneuver, he presented intense pain 10/10 in the lower back, radiating to the inner part of the right thigh and the groin. Difficulty walking and performing daily activities was established. The pain changed very little with the intake of NSAIDs. On physical examination, the patient had grade 1 obesity and normal blood pressure. There was evidence of a slight

decrease in the strength of the right foot during dorsiflexion. There were no other neurological deficits.

Diagnostic workshop

After performing imaging studies, a hernia was observed at the L4-L5 level in magnetic resonance imaging of the lumbar spine, located centrally and insinuating toward the body of S1 (Figure 1).

Treatment

The treatment of choice for the clinic of the patient who presented during this time was the performance of bilateral L3-L4, L4-L5, and L5-S1 facet block; in subsequent check-ups, she reported a notable decrease in progressive pain. After three months, he lost weight to a high standard body mass index. With the help of the rehabilitation service, he received education in spinal ergometry in daily activities (spine school). Pain decreased by 90%, referring only to weakness.

Evolution

Six months after the surgical procedure, it was decided to perform follow-up magnetic resonance imaging, which revealed reabsorption of the hernia (Figure 2).

A new control was carried out a year later since the patient did not present any regression in her symptoms during this period, evidencing hernia reabsorption in the magnetic resonance imaging (Figure 3).

Discussion

Conservative treatment of disc herniation and partial or complete spontaneous regression is not frequent. Some modifiable factors, such as obesity and poor ergonomics, may explain the reversibility once the risk factor has been removed. The decision to perform conservative treatment must be correlated with the patient's symptoms, such as pain, evolution, and disability. However, imaging studies indicate a lumbar disc protrusion; if the clinical signs are manageable, we recommend conservative treatment.

To demonstrate this phenomenon of spontaneous regression of the hernia, whether partial or complete, it is essential to identify the mechanisms behind this regression.

Cunha et al. indicated that the inflammation process is the main factor responsible for the regression of LDH. LDH has been associated with disruption of the annulus fibrosus (AF), extrusion of the nucleus pulposus (NP), and stimulation of nerve fibers, resulting in pain [9-11].

The first hypothesis is that the bulging disc shrinks and reduces in size due to gradual dehydration and shrinkage, which may explain the decreased signal intensity of the disc in follow-up MRI studies [9,10]. The second hypothesis states that disc regression due to the stress applied by the PLL leads to the retraction of the herniated disc fragment into the IVD space [12, 13]. The third hypothesis establishes enzymatic degradation and phagocytosis of the disc tissue due to the inflammatory reaction and neovascularization. This is the most remarkable mechanism. Describes an inflammatory response

in which the autoimmune system recognizes the extruded disc material as a 'foreign body' in the epidural vascular space of the vertebra. This causes neovascularization of the disc tissue and infiltration by inflammatory cells such as macrophages, granulocytes, and lymphocytes [9, 12, 14].

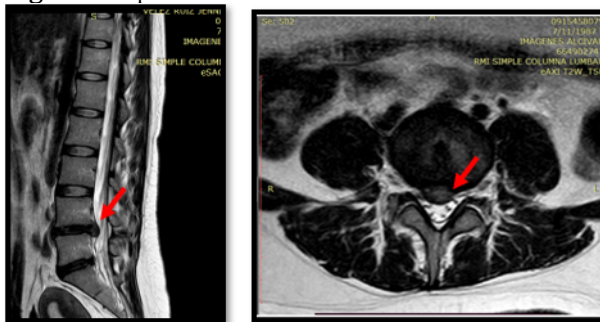
Conservative treatment, generally in a patient with symptoms and unexpected signs, is chosen for 3–6 weeks; among the primary indications, it is indicated that the patient remains active, except in the case of an acute process. In clinical practice, stretching exercises for the lumbar spine, known as McKenzie exercises, and core stabilization exercises, which include the abdominal, lumbar, and pelvic region muscles, are recommended in addition to pharmacological treatment [15, 16].

Surgical intervention is the preferred treatment method in patients with herniated discs with persistent pain, when there is root involvement manifesting with sciatic irritation and when there is a picture of disc displacement, nerve root compression that correlates with clinical conditions that negatively affect social life, foot drop, urinary and fecal incontinence or tail conditions [17, 18].

The study carried out where the treatment of disc herniation was assessed was conservative at 100%; however, patients who presented failure in said treatment underwent surgery, reaching 3.7% [19].

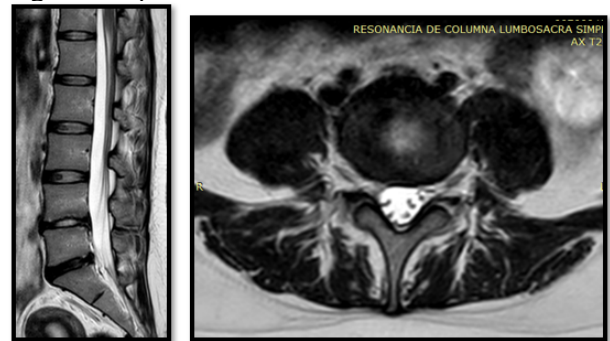
Whether spontaneous or induced, the resorption process requires long-term monitoring and follow-up to prevent complications in adjacent segments of the spine; in our study, we can show that the patient with conservative treatment had a notable improvement in her symptoms. This is how the follow-up at six and twelve months shows reabsorption of the herniated disc on MRI, followed by a significant improvement in its symptoms.

Figure 1. Spinal MRI.



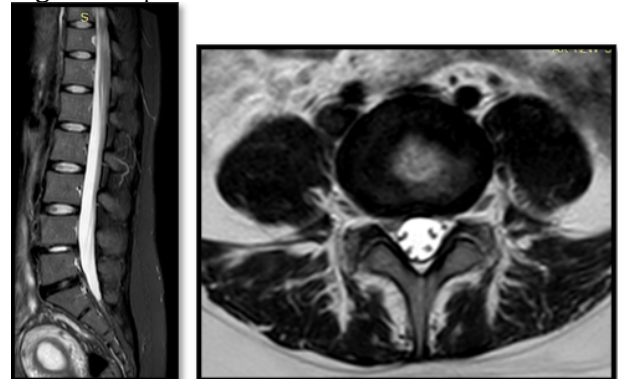
Left: Sagittal section: hernia expels in the L4-L5 space. Right: axial section: hernia protruding into the anterior subarachnoid space and narrowing of the preforaminal subarachnoid space on each side of the midline.

Figure 2. Spinal MRI 6 months.



Left: sagittal section with resorption of the hernia at the level of L4-L5. Right: axial cut shows reabsorption of hernia expels L4 - L5.

Figure 3. Spinal MRI 12 months.



Left: sagittal section, resorption of the hernia at the level of L4-L5 in 100%. Right: axial section showing hernia resorption.

Conclusions

In the present case of a herniated disc, there were modifiable factors such as obesity and poor ergonomics that, once corrected, contributed to the disappearance of spinal lesions and improvement of symptoms. Magnetic resonance imaging should be used to predict follow-up lumbar disc herniation regression after physical therapy.

References

1. Turk O, Antar V, Yaldiz C. Spontaneous regression of herniated nucleus pulposus: The clinical findings of 76 patients. *Medicine (Baltimore)*. 2019 Feb;98(8):e14667. doi: [10.1097/MD.00000000000014667](https://doi.org/10.1097/MD.00000000000014667). PMID: 30813213; PMCID: PMC6407986.

2. Wang R, Luo H. Regression of lumbar disc herniation with nonsurgical treatment: a case report. *J Int Med Res.* 2021 Jun;49(6):3000605211020636. doi: [10.1177/03000605211020636](https://doi.org/10.1177/03000605211020636). PMID: 34098752; PMCID: PMC8191079.
3. Lyu FJ, Cui H, Pan H, Mc Cheung K, Cao X, Iatridis JC, Zheng Z. Painful intervertebral disc degeneration and inflammation: from laboratory evidence to clinical interventions. *Bone Res.* 2021 Jan 29;9(1):7. doi: [10.1038/s41413-020-00125-x](https://doi.org/10.1038/s41413-020-00125-x). PMID: 33514693; PMCID: PMC7846842.
4. Aroche Lafargue Y, Pons Porrata LM, De La Cruz De Oña A, González Ferro I. Pathogenesis, clinical picture and magnetic resonance imaging diagnosis of herniated discs. *MEDISAN.* 2015 Mar ;19(3):391-402.
5. Schröder C, Nienhaus A. Intervertebral Disc Disease of the Lumbar Spine in Health Personnel with Occupational Exposure to Patient Handling-A Systematic Literature Review and Meta-Analysis. *Int J Environ Res Public Health.* 2020 Jul 4;17(13):4832. doi: [10.3390/ijerph17134832](https://doi.org/10.3390/ijerph17134832). PMID: 32635557; PMCID: PMC7370072.
6. Zhong M, Liu JT, Jiang H, Mo W, Yu PF, Li XC, Xue RR. Incidence of Spontaneous Resorption of Lumbar Disc Herniation: A Meta-Analysis. *Pain Physician.* 2017 Jan-Feb;20(1):E45-E52. PMID: [28072796](https://pubmed.ncbi.nlm.nih.gov/28072796/).
7. Zhong M, Liu JT, Jiang H, Mo W, Yu PF, Li XC, Xue RR. Incidence of Spontaneous Resorption of Lumbar Disc Herniation: A Meta-Analysis. *Pain Physician.* 2017 Jan-Feb;20(1):E45-E52. PMID: [28072796](https://pubmed.ncbi.nlm.nih.gov/28072796/).
8. Quiroz-Moreno R, Lezama-Suárez G, Gómez-Jiménez C. Disc alterations of lumbar spine on magnetic resonance images in asymptomatic workers. *Rev Med Inst Mex Seguro Soc.* 2008 Mar-Apr;46(2):185-90. English. PMID: [19133190](https://pubmed.ncbi.nlm.nih.gov/19133190/).
9. Cunha C, Silva AJ, Pereira P, Vaz R, Gonçalves RM, Barbosa MA. The inflammatory response in the regression of lumbar disc herniation. *Arthritis Res Ther.* 2018 Nov 6;20(1):251. doi: [10.1186/s13075-018-1743-4](https://doi.org/10.1186/s13075-018-1743-4). PMID: 30400975; PMCID: PMC6235196. doi: [10.1097/CM9.0000000000001990](https://doi.org/10.1097/CM9.0000000000001990).
10. Macki M, Hernandez-Hermann M, Bydon M, Gokaslan A, McGovern K, Bydon A. Spontaneous regression of sequestered lumbar disc herniations: Literature review. *Clin Neurol Neurosurg.* 2014 May;120:136-41. doi: [10.1016/j.clineuro.2014.02.013](https://doi.org/10.1016/j.clineuro.2014.02.013). Epub 2014 Feb 25. PMID: 24630494.
11. Hong J, Ball PA. IMAGES IN CLINICAL MEDICINE. Resolution of Lumbar Disk Herniation without Surgery. *N Engl J Med.* 2016 Apr 21;374(16):1564. doi: [10.1056/NEJMicm1511194](https://doi.org/10.1056/NEJMicm1511194). PMID: 27096582.
12. Hu C, Lin B, Li Z, Chen X, Gao K. Spontaneous regression of a large sequestered lumbar disc herniation: a case report and literature review. *J Int Med Res.* 2021 Nov;49(11):3000605211058987. doi: [10.1177/03000605211058987](https://doi.org/10.1177/03000605211058987). PMID: 34812080; PMCID: PMC8649452.
13. Wang Y, Liao SC, Dai GG, Jiang L. Resorption of upwardly displaced lumbar disk herniation after nonsurgical treatment: A case report. *World J Clin Cases.* 2020 Oct 6;8(19):4609-4614. doi : [10.12998/wjcc.v8i19.4609](https://doi.org/10.12998/wjcc.v8i19.4609). PMID: 33083425; PMCID: [PMC7559678](https://pubmed.ncbi.nlm.nih.gov/PMC7559678/).
14. Karademir M, Eser O, Karavelioglu E. Adolescent lumbar disc herniation: Impact, diagnosis, and treatment. *J Back Musculoskeletal rehab.* 2017;30(2):347-352. doi: [10.3233/BMR-160572](https://doi.org/10.3233/BMR-160572). PMID: 27858699.
15. Oktay K, Ozsoy KM, Dere UA, Cetinalp NE, Arslan M, Erman T, Guzel A. Spontaneous regression of lumbar disc herniations: A retrospective analysis of 5 patients. *Niger J Clin Pract.* 2019 Dec;22(12):1785-1789. doi: [10.4103/njcp.njcp_437_18](https://doi.org/10.4103/njcp.njcp_437_18). PMID: [31793490](https://pubmed.ncbi.nlm.nih.gov/31793490/).
16. Yang X, Zhang Q, Hao X, Guo X, Wang L. Spontaneous regression of herniated lumbar discs: Report of one illustrative case and review of the literature. *Clin Neurol Neurosurg.* 2016 Apr;143:86-9. doi: [10.1016/j.clineuro.2016.02.020](https://doi.org/10.1016/j.clineuro.2016.02.020). Epub 2016 Feb 16. PMID: 26907997.
17. Wan ZY, Shan H, Liu TF, Song F, Zhang J, Liu ZH, Ma KL, Wang HQ. Emerging Issues Questioning the Current Treatment Strategies for Lumbar Disc Herniation. *Front Surg.* 2022 Mar 28;9:814531. doi: [10.3389/fsurg.2022.814531](https://doi.org/10.3389/fsurg.2022.814531). PMID: 35419406; PMCID: PMC8999845.
18. Utter A, Cavanaugh D, Van Schouwen KF, Mascagni M, Walker M, Stone M. Spontaneous regression and near disappearance of a calcified herniated thoracic disc in a 44-year-old male: illustrative case. *J Neurosurg Case Lessons.* 2021 May 10;1(19):CASE 2130. doi: [10.3171/CASE2130](https://doi.org/10.3171/CASE2130). PMID: 35854829; PMCID: PMC9245764.

19. Gualpa G, Mosquera P, Vallejo S. Herniated Disc: Conservative vs. Surgical Treatment. Hospital Ecuadorian Institute of Social Security. Riobamba. 2020-2021. November 24, 2021; URL: [UNACH: 51000/8301](https://doi.org/10.61284/114).

Correo: villarroelr@hotmail.com
ORCID ORCID 0000-0002-0847-0344

Carlos Alberto Jaramillo Becerra, Physician from the National University of Loja (Loja, 2002). Specialist in traumatology and orthopedics from the University of Guayaquil (Guayaquil, 2013). High specialty in medicine> Medical and surgical care of spinal conditions by the National Autonomous University of Mexico (Federal District, 2017). Chief, Orthopedics and Traumatology Service, Alcívar Hospital, Guayaquil, Ecuador.
Correo: dr.jaramillobecerracarlos@gmail.com

ORCID <https://orcid.org/0009-0002-0680-4547>

Gabriel Machado, Treating Physician at the Alcívar Hospital Traumatology and Orthopedics Service.

Correo: gabrielmachado28-10@hotmail.com

ORCID <https://orcid.org/0009-0007-9306-8141>

Manuel Encalada, Treating Physician at the Alcívar Hospital Traumatology and Orthopedics Service.

Correo: manuencaespi@gmail.com

ORCID <https://orcid.org/0009-0000-0862-318X>

Jessica Tapia, Resident Physician of Traumatology and Orthopedics Hospital Alcívar.

Correo: jessivane19@hotmail.com

ORCID <https://orcid.org/0009-0008-8710-4705>

Statements

Ethics committee approval and consent to participate

Not required for clinical cases.

Publication Consent

Written permission was obtained from the patient to publish the images.

Conflicts of interest

The authors declare they have no conflicts of interest.

Author Information

Hugo Ernesto Villarroel Rovere, Specialist in Traumatology and Orthopedics from the University of Guayaquil (Guayaquil, 2004). Doctor of Medicine and Surgery from the University of Guayaquil. Orthopedic-Traumatologist, team member, and director of the postgraduate course in Orthopedics and Traumatology, Hospital Alcívar, Guayaquil, Ecuador.
Email: villarroelr@hotmail.com

Editor's Note

The Revista Actas Médicas (Ecuador) remains neutral regarding jurisdictional claims on published maps and institutional affiliations.

Received: March 11, 2023.

Accepted: May 19, 2023.

Published: June 12, 2023.

Editor: Dra. Mayra Ordonez Martinez.

Cite:

Villarroel H, Jaramillo C, Machado G, Encalada M, Tapia J. Herniated disc resorption without surgical treatment. Case report. Medical Records (Ecuador) 2023;33(1):55-60.



Copyright 2023, Hugo Ernesto Villarroel Rovere, Carlos Alberto Jaramillo Becerra, Gabriel Machado, Manuel Encalada, Jéssica Tapia. This article is distributed under the terms of the [Creative Commons CC BY-NC-SA 4.0 Attribution License](https://creativecommons.org/licenses/by-nc-sa/4.0/), which permits noncommercial use and redistribution provided the source, and the original author is cited.

Correspondence: Hugo Ernesto Villarroel Rovere

Email: villarroelr@hotmail.com

ORCID: 0000-0002-0847-0344

Address: Colonel 2301 and Azuay. Orthopedics and Traumatology Service, Alcívar Hospital, Guayaquil, Ecuador. Telephone: (5934) 3720100.